

# Effect of Low-Level Laser Irradiation on Bisphosphonate-Induced Osteonecrosis of the Jaws: Preliminary Results of a Prospective Study

Matteo Scoletta, D.D.S.,<sup>1</sup> Paolo G. Arduino, D.D.S., M.Sc.,<sup>2</sup> Lucia Reggio, D.D.S.,<sup>1</sup> Paola Dalmasso, M.Sc.,<sup>3</sup> and Marco Mozzati, M.D., D.D.S.<sup>1</sup>

## Abstract

**Objective:** The aim of this study was to detail the clinical efficacy of low-level laser therapy (LLLT) for the management of bisphosphonate-induced osteonecrosis of the jaws (ONJ-BP). **Background:** ONJ-BP is the correct term, recently emerged, to describe a significant complication in a subset of patients receiving drugs such as zoledronic acid, pamidronate, and alendronate. No definitive standard of care has been set for ONJ-BP and no definitively agreed guidelines have been provided. There is currently no consensus on the correct approach to the issue. **Materials and Methods:** The investigators studied a prospective cohort of 20 patients affected by ONJ-BP, who received biostimulation with a pulsed diode laser (GaAs). Patients were exposed to a 904-nm infrared laser (50 kHz, 28.4 J/cm<sup>2</sup> energy density, 40% duty cycle, spot size 0.8 cm). Outcome variables were the size of lesions, edema, visual analogue score of pain, presence of pus, fistulas, and halitosis. Preoperative results were compared with the postoperative outcome and statistically evaluated. **Results:** Four weeks after LLLT, a statistically significant difference was observed for reported pain ( $p=0.0001$ ), clinical size ( $p=0.0034$ ), edema ( $p=0.0005$ ), and presence of pus and fistulas ( $p=0.0078$  and  $p=0.03$ , respectively). **Conclusion:** This study suggests that LLLT would appear to be a promising modality of treatment for patients with ONJ-BP, providing that clinical efficacy is safe and well tolerated, especially by those patients who require conservative treatment. Of course, this needs to be addressed further in larger and randomly controlled studies in different clinical settings.

## Introduction

LOW-LEVEL LASER therapy (LLLT) is an innovative approach, increasingly used in medicine, which has been shown to have several different effects, including pain relief, wound healing, and nerve regeneration. It has potential antimicrobial and biostimulating effects when applied to oral tissues by improving wound healing,<sup>1,2</sup> enhancing epithelization after periodontal surgery,<sup>3,4</sup> minimizing oedema after third molar surgery,<sup>5</sup> and preventing induced oral mucositis.<sup>6</sup> It has been proven that LLLT stimulates the proliferation of cells<sup>7</sup> and the formation of new lymphatic and blood vessels.<sup>8</sup>

Bisphosphonate-induced osteonecrosis of the jaws (ONJ-BP) is the correct term, recently emerged, to describe a significant complication in a subset of patients receiving a class

of agents used to treat osteoporosis and malignant bone metastases.<sup>9–11</sup> The main pathogenesis of ONJ-BP still remains to be completely elucidated; apparently, the ability of bisphosphonates to inhibit vascular endothelial growth factor and formation of new capillaries may be accentuated in the jaw bones with high vascularity and bone turnover.<sup>12</sup>

It has been reported that LLLT can improve bone mineralization.<sup>13–15</sup> The effect of LLLT on bone regeneration has been the focus of more recent research, including within dentistry. Studies have investigated the ability of low-level laser irradiation to stimulate both bone production and bone-implant interaction.<sup>14</sup> For these reasons, it can be postulated that laser biostimulation may be helpful in treating ONJ-BP.<sup>16</sup>

The aim of this study was to estimate the effects and the efficacy of LLLT on the outcome of ONJ-BP.

<sup>1</sup>Oral Surgery Unit, Dentistry Section, Department of Clinical Physiopathology, University of Turin, Turin, Italy.

<sup>2</sup>Oral Medicine Unit, Dentistry Section, Department of Clinical Physiopathology, University of Turin, Turin, Italy.

<sup>3</sup>Medical Statistics Unit, Department of Public Health and Microbiology, University of Turin, Turin, Italy

## Materials and Methods

### Study sample and inclusion criteria

Consecutive cases of exposed bone in the mandible or maxilla after treatment with bisphosphonates (BPs) were prospectively included in this dataset. In accordance with published recommendations, ONJ-BP was diagnosed using a two-step approach consisting of clinical identification of exposed bone in the maxillofacial area, occurring spontaneously or in association with dental surgery, without evidence of healing, and excluding lesions derived from metastatic jaw disease or resulting from radiotherapy.<sup>17</sup>

Patients diagnosed with ONJ-BP at the Oral Surgery Unit, Department of Clinical Physiopathology, Turin Hospital, Italy, between April 2006 and May 2008, were selected for the present study.

At the time of the diagnosis, a computerised clinical file was created for the patient, which recorded information on age, gender, presence of any systemic disease, and use of any drugs. In particular, each patient was asked for a detailed history concerning the use, dose, frequency, and the duration of therapy with BPs. Patients who had been treated with zoledronic acid (ZOL) received 4 mg intravenously for 15 min monthly; those treated with pamidronate (PAM) received 90 mg for 1 h intravenously over the same period; and those with alendronate (ALE) received 70 mg weekly orally.

All patients were clinically evaluated by a skilled group of oral health care providers, who recorded the clinical aspect of the lesions, size and sites of oral involvement, as well as signs of secondary infection.

The extent of ONJ-BP was staged according to previous published classification:<sup>18</sup> stage I – exposed/necrotic bone in patients who are asymptomatic, <1 cm (stage IA) and >1 cm (stage IB); stage II – exposed/necrotic bone in patients with pain, <2 cm (stage IIA) and >2 cm (stage IIB); stage III – multiple lesions (stage IIIA) and multiple lesions with one or more of pathologic fracture, extra-oral fistulas, or osteolysis extending to the inferior border of the mandible (stage IIIB). Nevertheless, lesions larger than 2.5 cm were excluded from the present study.

The local ethical committee approved the study protocol. All patients were informed of the nature of the experimental procedures and consent was obtained.

### Laser procedure

A Lumix 2 HFPL Dental Device (Prodent Italia S.r.l., Pero, Milan, Italy) was used. The Lumix 2 is a desktop laser instrument with a pulsed diode that provides peak powers of up to 40 W for very effective photonic tissue penetration. The power is modulated so that it is adjustable from 10 to 100%. This allows the average power to be matched to the specific needs of the patient and achieves high-depth tissue penetration while providing gentle average power levels. The laser beam is transmitted through fiber-optic cables and is guided by a red LED light (with an output power of 7 mW, which represents less than 4% of the whole power of the infrared) at the treatment probe aperture to ensure patient comfort and treatment accuracy.

Each patient underwent 10 laser irradiation sessions over a period of 20 days: four sessions in the first week of treatment, three sessions in the second week, and another three in

the last week. Patients were exposed to a pulsed 904-nm infrared laser (50 kHz, 28.4 J/cm<sup>2</sup> energy density, 40% duty cycle, spot size 0.8 cm). According to the manufacturer's instructions, in each session the laser was used in slight contact with the tissues for 15 min: 59 J at 60 kHz for 5 min, and 120 J at 40 kHz for 10 min.

### Clinical assessments

A single skilled examiner (L.R.) recorded the size of lesion, edema, and pain; moreover, presence of pus, fistulas, and halitosis were also detailed. Clinical measurements were performed 1 h before the laser procedure (T0) and 28 days after (T1). Facial edema was evaluated by measuring the distance from the corner of the mouth to the attachment of the ear lobe following the bulge of the cheek, and the distance from the outer canthus of the eye to the angle of the mandible.

Severity of patient pain perception was assessed using a Visual Analogue Scale (VAS). The VAS consisted of a 10-cm horizontal line marked 0 (= no pain) to 10 (= most severe pain experienced). Patients were requested to mark the scale at each visit. Complete resolution of the symptoms (no symptoms) was defined as the absence of any discomfort, corresponding to a zero VAS score. Partial response, worsening, or persistence of the patient's condition meant a decrease, increase, or no change at all in the patient's score. The difference between baseline and endpoint scores numerically expresses the clinical and symptomatic improvement.

At T1, the evolution of the disease was detailed as follows: resolution of symptoms (RS) – no pain or symptoms of infections; clinical achievement (CA) – complete or partial covering of the previously exposed bone with re-epithelization,

TABLE 1. SOME PATIENTS' CHARACTERISTICS AT THE TIME OF DIAGNOSIS

Variables	No.	%	
Primary disease	Breast cancer	6	30
	Multiple myeloma	6	30
	Osteoporosis	5	25
	Prostate cancer	3	15
BP used*	ZOL	12	60
	ALE	6	30
	ZOL + PAM	2	10
Other medications	Steroids	5	25
	Chemiotherapy	13	65
Smoke cigarettes	Some or every day	2	10
Alcohol consumption	Some or every day	0	0
Supposed cause of ONJ-BP <sup>§</sup>	Dental extraction	15	75
	Periodontal diseases	2	10
	Prosthetic trauma	1	5
	Failure of dental implants	1	5
	Oral surgery	1	5
ONJ-BP stage <sup>18</sup>	IA	1	5
	IB	1	5
	IIA	13	65
	IIB	3	15
	IIIA	2	10

\*ZOL: zoledronic acid; PAM: pamidronate; ALE: alendronate.

<sup>§</sup>Bisphosphonate-induced osteonecrosis of the jaws.

TABLE 2. THE COMPARISON OF SELECTED DATA AT T0 (BEFORE) AND T1 (AFTER) TREATMENT WITH LLLT

	T0	T1	p*
Pain (VAS score)	7 (0–9)	2 (0–4)	0.0001
Clinical size	1 (0–2.5)	0.4 (0–5)	0.0034
Edema	4 (0–8)	0 (0–4)	0.0005
Pus			
Yes	12	4	0.0078
No	8	16	
Fistulas			
Yes	8	2	0.03
No	12	18	
Halitosis			
Yes	11	7	0.125
No	9	13	

\*Wilcoxon’s signed rank test.

with no signs of oral or cutaneous draining fistulas; failure (FA) – progressive exposure of necrotic bone or additional complication (e.g., fracture).

The typical follow-up schedule was 1, 2, 3, 6, 9, and 12 mo postoperatively in the first year, followed by every 3 mo thereafter.

*Statistical analysis*

Describing general information, data were reported as means ± standard deviation, unless otherwise described. Wilcoxon’s signed rank test was used to calculate the significance of the outcome data at T1. The results were statistically compared using the Fisher’s exact test for qualitative variables and the Mann–Whitney U test for the quantitative data. P values of ≤0.05 were considered to be statistically significant. SPSS (SPSS for Windows, version 11, SPSS Inc., Chicago, IL) statistical software was utilized.

**Results**

Overall baseline clinical characteristics of the study population are reported in Table 1. The mean duration of follow-up was 242 days (±38). A total of 20 patients took part in the

study, of which 14 were women (70%). The mean age at presentation was 71.3 years (±9.86). Patients were treated with BPs for a mean of 42.95 mo (±32.16) at the time of diagnosis. Usually, in our experience, the continuation of BPs treatment after ONJ diagnosis was left to the discretion of the treating physicians. However, in this series, no patients discontinued BPs. We also examined patient pain perception after each procedure, and the VAS score was 0 in all cases.

Differences in the reported parameters between T0 and T1 are detailed in Table 2 (Figs. 1 and 2). A statistically significant difference was observed for reported pain, clinical size, edema, and presence of pus and fistulas. No reported complications or therapy side effects were observed in any of the patients treated.

Table 1 reported the clinical stage at T0. At T1, four patients were classified as stage 0, three as stage IA, four as stage IB, and nine as stage IIA. Eight patients (40%) remained stable between T0 and T1, whereas 12 patients (60%) improved with RS and CA. The results of staging before and after the treatment are shown in Fig. 3. No variables were found to be significant predictors of the outcome of ONJ-BP lesions, even for patients on i.v. BPs (especially those on ZOL). Those who also underwent chemotherapy treatment seemed to have a worse prognosis (data not shown).

After T1, patients were followed up every 8 mo on average. Symptoms remained stable in 17 patients and the size of lesions remained stable in 16 patients. Two patients had FA, developing progressive exposure of necrotic bone, with no pain reported for one case (50%). During the follow-up period, three patients developed new lesions with pus, two patients had new fistulas, and two patients reported halitosis again.

**Discussion**

To date, no definitive standard of care has been set for ONJ-BP and no definitively agreed guidelines have been provided. There is no consensus on the surgical or non-surgical approach to the issue. Moreover, at present, there is little prospective literature on the long-term management and outcome of ONJ-BP patients. For most patients, a complete cure is not possible. However, a complete resolution of

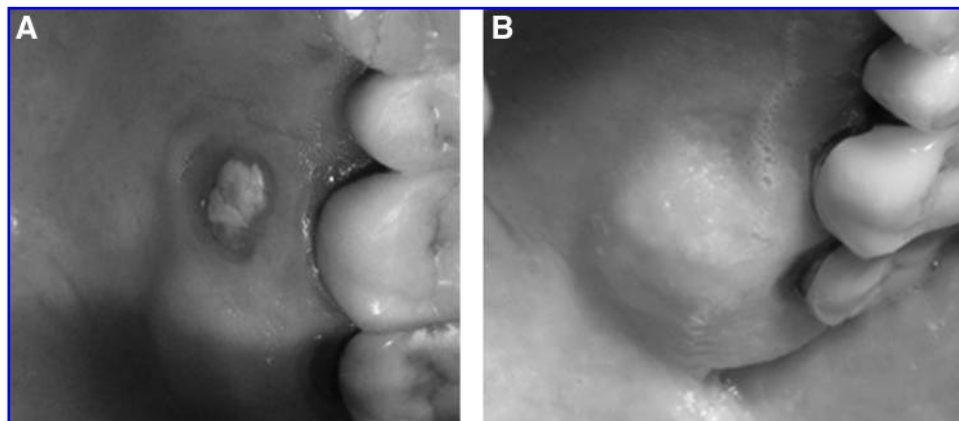
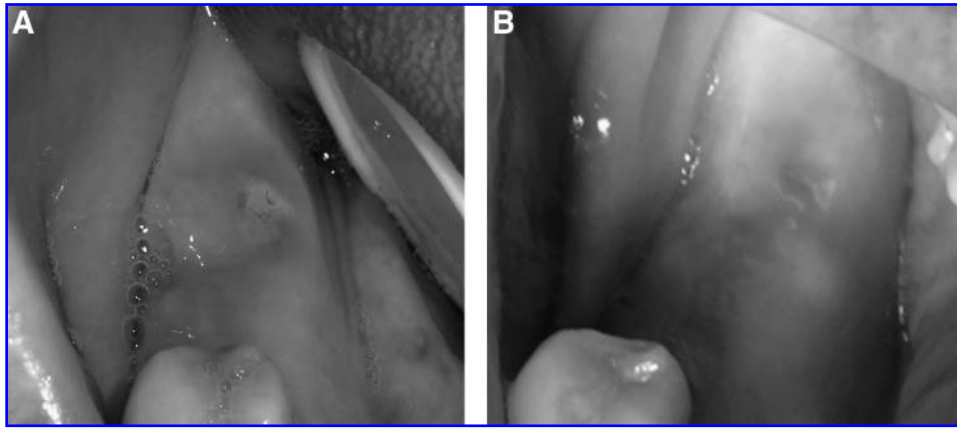


FIG. 1. Fifty-year-old women with ONJ-BP of left hard palate. Patient presented with pain and alythosis. (A) Initial appearance. (B) 4 mo after LLLT.



**FIG. 2.** Seventy-year-old women with ONJ-BP of right mandible. Patient presented with severe pain after a dental extraction. (A) Initial appearance. (B) 3 mo after LLLT.

symptoms and partial clinical achievement should at least be one of the primary goals in the management of ONJ-BP.

Numerous clinical protocols to treat areas of exposed bone have been proposed, reporting reductions or even resolutions of clinical signs using conservative treatment. However, extensive and radical surgical resections have rarely resulted in long-term successful wound closure and have sometimes led to worsening of the diseases.<sup>18–21</sup>

Controversies about tissues biostimulating with LLLT still remain; a lack of homogeneous reporting of physical and biological variables makes the summing up of the results particularly complicated.<sup>22</sup> In vitro phototherapy seemed to influence cell growth and protein production, and it has possibly been shown to act as a proliferative stimulus on osteoblast-like cells.<sup>23,24</sup>

The use of LLLT in ONJ-BP has been reported recently,<sup>16</sup> showing complete clinical success or improvements in more than 80% of cases, in contrast to previous retrospective studies analyzing conservative treatment. This study was designed as a prospective investigation to detail the effectiveness of laser therapy in managing oral necrotic lesions.

In recent years, laser technology has been used to improve the clinical results of bone surgeries and to promote a more comfortable postoperative period and quicker healing. For

this reason, LLLT could be taken as a possible choice in the management of bone lesions in ONJ-BP-positive patients.

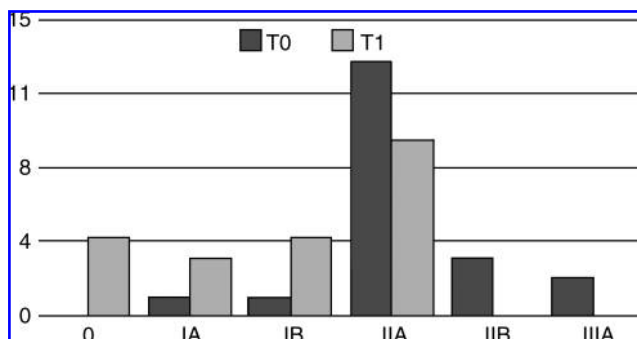
The general population characteristics of the presented cohort are comparable to those previously reported. Our results showed that the use of LLLT in the management of ONJ-BP has a significant effect on reducing pain and clinical parameter of inflammation. Our findings might have a significant clinical impact, since LLLT is easy to perform, does not increase morbidity, or present side effects. Obtained results were also stable during the follow-up period. According to the manufacturer's instructions, two protocols of irradiation have been used, the lower with an antimicrobial effect, the other with a biostimulating effect. Whilst healing was the first aim of the study, another purpose was controlling inflammation around involved tissues by possibly decreasing infection.

We decided to exclude lesions larger than 2.5 cm because, in our experience, these patients typically have pain that impacts the quality of life, and surgical debridement, even if it is not completely resolvable, may offer long-term palliation with resolution of acute infection and pain.<sup>25</sup>

The reduction of the necrotic lesions obtained at T1 is, however, imputable to the re-epithelization of the superficial mucosa more than to a real improvement of the deep bony lesion. Similar to these findings, recent studies have further focused on laser impact on cell-growth processes involved in wound repair.<sup>26</sup>

We reported that use of chemotherapy reduced the healing rate, even if in a non-statistical matter, and this is similar to recent findings.<sup>27</sup>

Moreover, it is always important to keep in mind that many of these patients have a compromised systemic condition, usually not compatible with more radical treatments, and a low expectation of life. For this reason, obtaining a reasonable quality of life can be considered as the most favourable goal, remembering that the standard objective for controlling ONJ-BP should always be prevention.<sup>28,29</sup> In our series, for example, pain score showed a statistically significant improvement, and patients reported a great enhancement in quality of life. LLLT has been shown to promote an increase in the synthesis and release of endorphins, with reduced sensory nerve conduction.<sup>30,31</sup>



**FIG. 3.** Disease stages in 20 patients who underwent SLLLT before and 1 mo after treatment. Evaluation of preoperative and postoperative staging revealed a statistically significant improvement ( $p < 0.05$ ).

## Conclusion

This study suggests that LLLT currently appears to be a possible treatment for patients with ONJ-BP. It significantly improved symptoms, even for those patients with bone exposure still visible. In many cases, LLLT decreased the size of lesions safely and was well tolerated, especially in those patients who required conservative treatment. Whilst these results are not conclusive and are more of a step forward in the enhanced management of this rare condition, it would be very interesting to know if this statement would be the same with a greater number of patients.

## Disclosure Statement

No competing financial interests exist.

## References

- Gál, P., Mokry, M., Vidinsky, B., et al. (2009). Effect of equal daily doses achieved by different power densities of low-level laser therapy at 635 nm on open skin wound healing in normal and corticosteroid-treated rats. *Lasers Med. Sci.* 24, 539–547.
- Gál, P., Vidinsky, B., Toporcer, T., et al. (2006). Histological assessment of the effect of laser irradiation on skin wound healing in rats. *Photomed. Laser Surg.* 24, 480–484.
- Ozcelik, O., Cenk Haytac, M., Kunin, A., and Seydaoglu, G. (2008). Improved wound healing by low-level laser irradiation after gingivectomy operations: a controlled clinical pilot study. *J. Clin. Periodontol.* 35, 250–254.
- Amorim, J.C., de Sousa, G.R., de Barros Silveira, L., Prates, R.A., Pinotti, M., and Ribeiro, M.S. (2006). Clinical study of the gingiva healing after gingivectomy and low-level laser therapy. *Photomed. Laser Surg.* 24, 588–594.
- Markovic, A., and Todorovic, L.J. (2007). Effectiveness of dexamethasone and low-power laser in minimizing oedema after third molar surgery: a clinical trial. *Int. J. Oral Maxillofac. Surg.* 36, 226–229.
- Antunes, H.S., de Azevedo, A.M., da Silva Bouzas, L.F., et al. (2007). Low-power laser in the prevention of induced oral mucositis in bone marrow transplantation patients: a randomized trial. *Blood* 109, 2250–2255.
- Pourzarandian, A., Watanabe, H., Aoki, A., et al. (2004). Histological and TEM examination of early stages of bone healing after Er:YAG laser irradiation. *Photomed. Laser Surg.* 22, 342–350.
- Polosukhin, V.V. (2000). Ultrastructure of the blood and lymphatic capillaries of the respiratory tissue during inflammation and endobronchial laser therapy. *Ultrastruct. Pathol.* 24, 183–189.
- Marx, R.E., Sawatary, Y., Fortin, M., and Broumand, V. (2005). Bisphosphonates-induced exposed bone (osteonecrosis/osteopetrosis) of the jaws: risk factors, recognition, prevention and treatment. *J. Oral Maxillofac. Surg.* 63, 1567–1575.
- Migliorati, C.A., Schubert, M.M., Peterson, D.E., and Seneda, L.M. (2005). Bisphosphonate-associated osteonecrosis of mandibular and maxillary bone: an emerging oral complication of supportive cancer therapy. *Cancer* 104, 83–93.
- Ruggiero, S.L., Gralow, J., Marx, R.E., et al. (2006). Practical guidelines for the prevention, diagnosis, and treatment of osteonecrosis of the jaw in patients with cancer. *J. Oncol. Pract.* 2, 7–14.
- Sarin, J., DeRossi, S.S., and Akintoye, S.O. (2008). Updates on bisphosphonates and potential pathobiology of bisphosphonate-induced jaw osteonecrosis. *Oral Diseases* 14, 277–285.
- Pires Oliveira, D.A., de Oliveira, R.F., Zangaro, R.A., and Soares, C.P. (2008). Evaluation of low-level laser therapy of osteoblastic cells. *Photomed. Laser Surg.* 26, 401–404.
- Martinasso, G., Mozzati, M., Pol, R., Canuto, R.A., and Muzio, G. (2007). Effect of superpulsed laser irradiation on bone formation in a human osteoblasts-like cell line. *Minerva Stomatol.* 56, 27–30.
- Pinheiro, A.L., and Gerbi, M.E. (2006). Photoengineering of bone repair processes. *Photomed. Laser Surg.* 24, 169–178.
- Vescovi, P., Merigo, E., Manfredi, M., et al. (2008). Nd:YAG laser biostimulation in the treatment of bisphosphonate-associated osteonecrosis of the jaw: clinical experience in 28 cases. *Photomed. Laser Surg.* 26, 37–46.
- Weitzman, R., Sauter, N., Eriksen, E.F., et al. (2007). Critical review: updated recommendations for the prevention, diagnosis, and treatment of osteonecrosis of the jaw in cancer patients – May 2006. *Crit. Rev. Oncol. Hematol.* 62, 148–152.
- Marx, R.E. (2007). Oral and Intravenous Bisphosphonate-Induced Osteonecrosis of the Jaws: History, Etiology, Prevention, and Treatment. Hanover Park, IL: Quintessence Publishing Co., Inc.
- Boonyapakorn, T., Schirmer, I., Reichart, P.A., Sturm, I., and Massenkeil, G. (2008). Bisphosphonate-induced osteonecrosis of the jaws: prospective study of 80 patients with multiple myeloma and other malignancies. *Oral Oncol.* 44, 857–869.
- Wutzl, A., Biedermann, E., Wanschitz, F., et al. (2008). Treatment results of bisphosphonate-related osteonecrosis of the jaws. *Head Neck* 30, 1224–1230.
- Marx, R.E., Cillo, J.E., Jr., and Ulloa, J.J. (2007). Oral bisphosphonate-induced osteonecrosis: risk factors, prediction of risk using serum CTX testing, prevention, and treatment. *J. Oral Maxillofac. Surg.* 65, 2397–2410.
- Vescovi, P., Merigo, E., Meleti, M., Fornaini, C., Nammour, S., and Manfredi, M. (2007). Nd:YAG laser biostimulation of bisphosphonate-associated necrosis of the jawbone with and without surgical treatment. *Br. J. Oral Maxillofac. Surg.* 45, 628–632.
- Fujihara, N.A., Hiraki, K.R., and Marques, M.M. (2006). Irradiation at 780 nm increases proliferation rate of osteoblasts independently of dexamethasone presence. *Laser Surg. Med.* 38, 332–336.
- Nicola, R.A., Jorgetti, V., Rigau, J., Pacheco, M.T., dos Reis, L.M., and Zangaro, R.A. (2003). Effect of low-power GaAlAs laser (660 nm) on bone structure and cell activity: an experimental animal study. *Laser Med. Sci.* 18, 89–94.
- Advisory Task Force on Bisphosphonate-Related Osteonecrosis of the Jaws, American Association of Oral and Maxillofacial Surgeons (2007). American Association of Oral and Maxillofacial Surgeons position paper on bisphosphonate-related osteonecrosis of the jaws. *J. Oral Maxillofac. Surg.* 65, 369–376.
- Poste, W., Wrone, D.A., Dover, J.S., et al. (2005). Low-level laser therapy for wound healing: mechanism and efficacy. *Dermatol. Surg.* 31, 334–340.
- Van den Wyngaert, T., Claeys, T., Huizing, M.T., Vermorcken, J.B., and Fossion, E. (2009). Initial experience with conservative treatment in cancer patients with osteonecrosis of the jaw (ONJ) and predictors of outcome. *Ann. Oncol.* 20, 331–336.

28. Dimopoulos, M.A., Kastiris, E., Bamia, C., et al. (2009). Reduction of osteonecrosis of the jaw (ONJ) after implementation of preventive measures in patients with multiple myeloma treated with zoledronic acid. *Ann. Oncol.* 20, 117–120.
29. Ripamonti, C.I., Maniezzo, M., Campa, T., et al. (2009). Decreased occurrence of osteonecrosis of the jaw after implementation of dental preventive measures in solid tumour patients with bone metastases treated with bisphosphonates. The experience of the National Cancer Institute of Milan. *Ann. Oncol.* 20, 137–145.
30. Ilbuldu, E., Cakmak, A., Disci, R., and Aydin, R. (2004). Comparison of laser, dry needling, and placebo laser treatments in myofascial pain syndrome. *Photomed. Laser Surg.* 22, 306–311.
31. Pozza, D.H., Fregapani, P.W., Blessmann Weber, J.B., et al. (2008). Analgesic action of laser therapy (LLLT) in an animal model. *Med. Oral Patol. Oral Cir. Buccal.* 13, E648–652.

Address correspondence to:  
*Dr. Paolo G. Arduino, D.D.S., M.Sc.*  
*Division of Otorhinolaryngology, Department of*  
*Clinical Physiopathology*  
*Oral Medicine Section, University of Turin*  
*Unito Lingotto Dental Institute c/o Lingotto*  
*Via Nizza 230, 10126 Turin*  
*Italy*  
*E-mail: paolo.arduino@gmail.com*